

The treatment of heel flap injuries in spoke Wheel accidents amongst Young children

G. Trompen, Cast Technician
 G. Elzinga, Cast Technician
 H. Spits, Cast Technician
 Dr. R.J Klücks, surgeon

A. Post, Cast Technician
 M.van Gent, Cast Technician

J.G Alblas, Physician assistant surgery

Introduction

A casestudy of 11 cases using hydrobalance-PHMB amongst young children with a spoke injury to decrease hospital visits and to make the treatment childfriendly.

Methods

11 children (average age 5 years old) were treated with Hydrobalance and foambandage. The standard procedure was 1 day silversulfadiazine and then hydrobalance-PHMB covered with a foambandage fixated with a cork splint. The Hydrobalance-PHMB then is let to dry, like the effect of a donorsite, and the pieces that let go were cut off. During the research time the patient was inspected every 3 days and the Hydrobalance was left intact.

Results

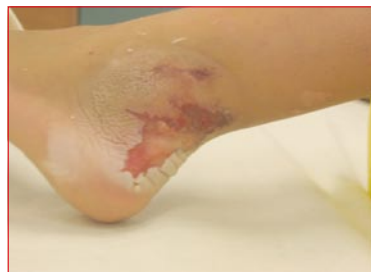- No woundinfection because of antiseptics in the Hydrobalance.
- In all cases the Hydrobalance dried and no change of bandages was necessary which results into less hospital visitations.
- Because no pain sensation occurred during the change of bandages the experience was less traumatic for child and parent.
- After 1 - weeks surface Epithelisation occurred.

Conclusions

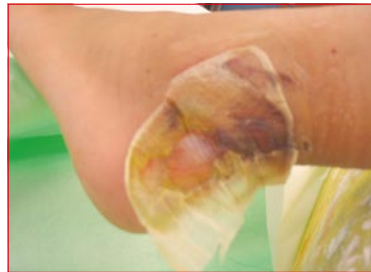
- childfriendly (bandages are changed only twice)
- rapid healing, no pain
- cost effective, less hospital visits
- Hydrobalance-PHMB has a surplus value in the treatment protocol for spoke injuries.

Case 1

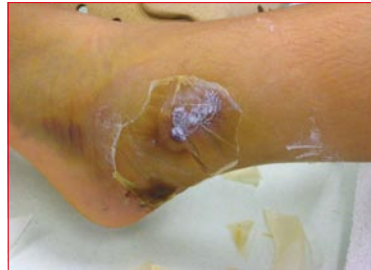Start with Suprasorb® X-PHMB after 24hr Flammazine. 09-06-2008



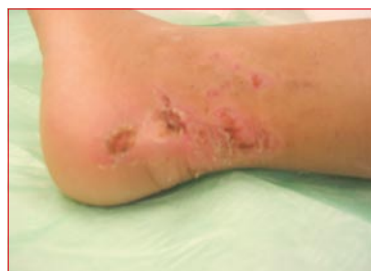The Suprasorb® X PHMB dries out at the edge of the wound. 12-06-2008



Piece of the Suprasorb® X-PHMB that let go were cut off.

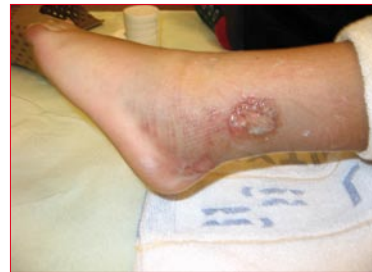

Suprasorb® X-PHMB came off the wound, full epithelisation. 18-06-2008

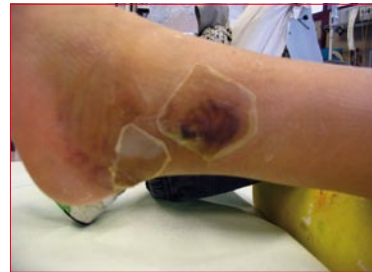

Case 2

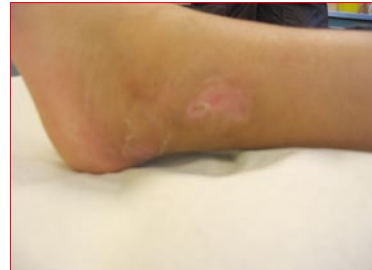A difficult to heal flap injury with infection and pain. 2-3-2009



Application of Suprasorb® X-PHMB. The egde is drying out. 8-3-2009

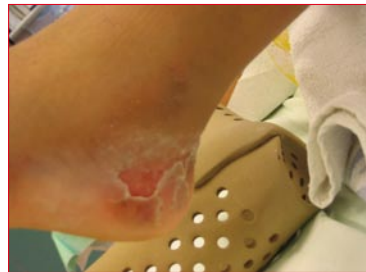

Full epithelisation. 16-03-2009

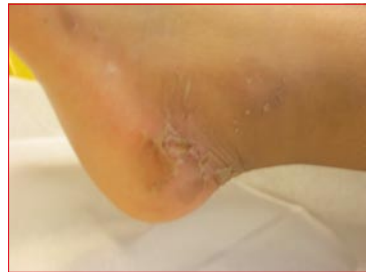

Case 3

Start with Suprasorb® X-PHMB 04-06-2008

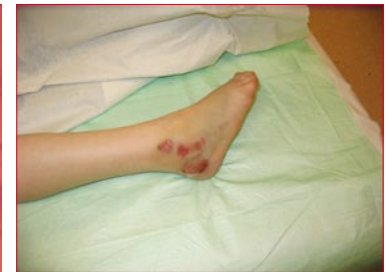

Healed within 5 days. 09-06-2008

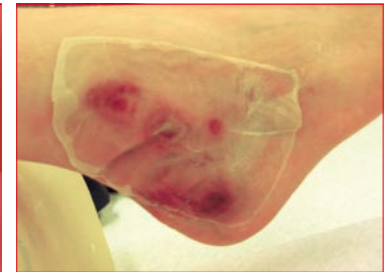


Case 4

Painful heal flap injury, painless after application Suprasorb® X-PHMB 24-02-2009



Rapid healing and good visibility on the wound through the Suprasorb® X-PHMB.



No bandage change necessary

